

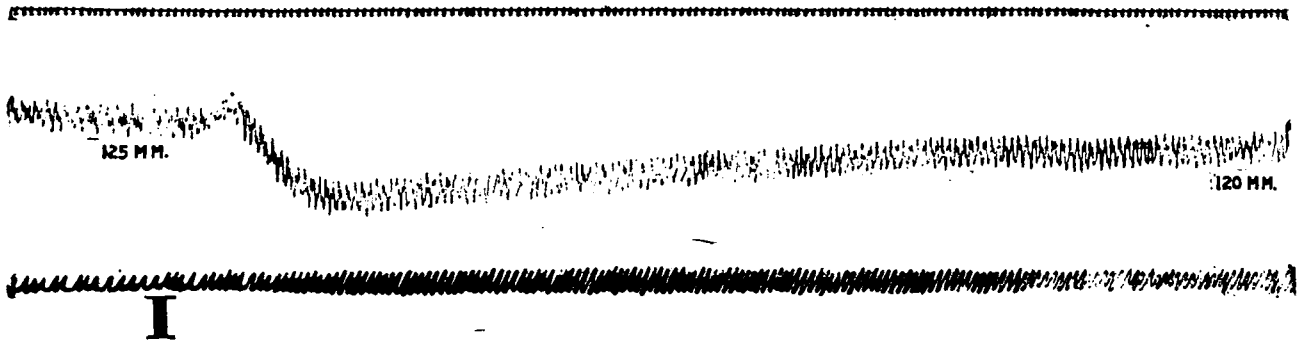Fig. 1.—Dec. 21, 1910. Dog, 6 kilos; ether anesthesia. Jugular injection at I, of 1 c.c. extract of dog chorioid. Uppermost line, timer marking seconds; second line, blood-pressure; third line, respiration.

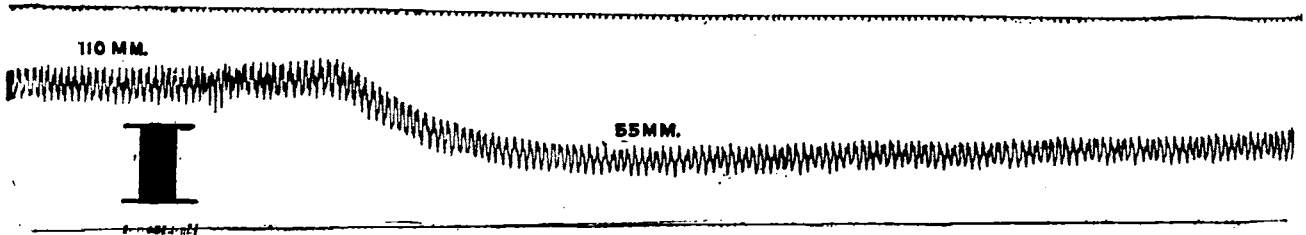


Fig. 4.—Dec. 28, 1910. Dog, 12 kilos; ether anesthesia. Jugular injection, at I, of 12 c.c. cerebrospinal fluid from a patient with cerebral edema of traumatic origin. Lines as before.




Fig. 6.—Dec. 31, 1910. Same dog as in Figure 5. Injection, at I, of 10 c.c. cerebrospinal fluid from same case (Fig. 5) of delirium tremens. Lines as before.




Fig. 7.—Jan. 3, 1911. Dog, 6 kilos; ether anesthesia. Jugular injection, at I, of 30 c.c. cerebrospinal fluid from an individual recovering from mild attack of delirium tremens. Lines as before.

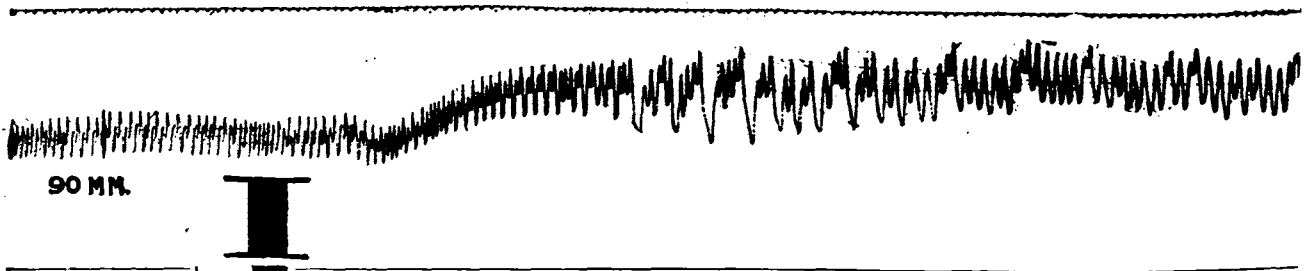


Fig. 8.—Dec. 10, 1910. Dog, 11 kilos; ether anesthesia. Jugular injection, at I, of 0.75 c.c. pituitary extract. Lines as before.




Fig. 9.—Dec. 30, 1910. Dog, 12.5 kilos; ether anesthesia. Jugular injection, at I, of 1 c.c. extract of human chorioid plus 1 c.c. of pituitary extract. Lines as before.